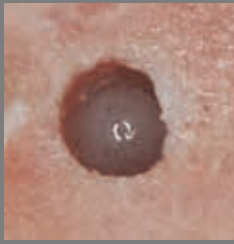


See The Difference Below

Osteotomies Created With Standard Drills




1. Osteotomy prepared in porcine Tibia with standard fluted drills




2. uCT radiograph of the above osteotomy



3. Histology cross section of implant placed in osteotomy prepared using standard drills at Day 1

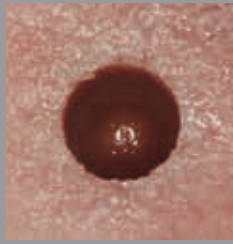


4. uCT radiograph of full length osteotomy prepared with standard drills

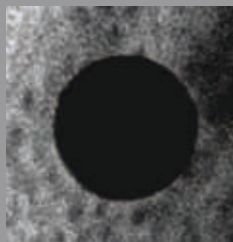


5. uCT cross section of implant placed in osteotomy prepared with standard drills at Day 1

Osteotomies Created With Densah™ Bur Clockwise Cutting




1. Osteotomy prepared in porcine Tibia with Densah Bur rotating clockwise (cutting)




2. uCT radiograph of the above osteotomy



3. Histology cross section of implant placed in osteotomy prepared using Densah Burs rotating clockwise at Day 1

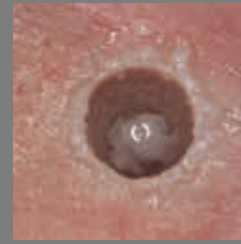

4. uCT radiograph of full length osteotomy prepared with Densah Burs rotating clockwise

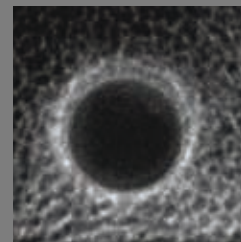


5. uCT cross section of implant placed in osteotomy prepared with Densah Bur rotating clockwise at Day 1

Osteotomies Created With Densah Bur Counterclockwise Osseodensification



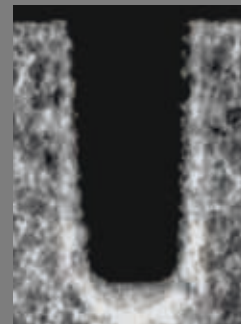
1. Osteotomy prepared in porcine Tibia with Densah Burs rotating counterclockwise (Osseodensification)



2. uCT radiograph of the above osteotomy



3. Histology cross section of implant placed in osteotomy prepared using Densah Burs rotating counterclockwise at Day 1



4. uCT radiograph of full length osteotomy prepared with Densah Burs rotating counterclockwise



5. uCT cross section of implant placed in osteotomy prepared with Densah Bur rotating counterclockwise at Day 1