

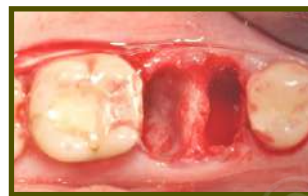Osseodensification

Molar Septum Expansion Protocol with the Densah™ Burs*

- SEPARATE MOLAR ROOTS AT THE FURCATION WITHOUT COMPROMISING THE INTEGRITY OF THE SEPTUM.
- USE PILOT DRILL IN CLOCKWISE MODE TO A DEPTH THAT IS 1 MM DEEPER THAN THE PLANNED IMPLANT LENGTH
- USE THE SUBSEQUENT DENSASH™ BURS IN SMALLER INCREMENTS TO EXPAND THE OSTEOTOMY AND TO INCREASE BONE PLASTICITY
- IMPLANT PLACEMENT SHOULD BE EITHER AT THE CREST OR SUB-CREST LEVEL
- FILL THE GAP WITH A BONE GRAFT MATERIAL IF NEEDED; PREFERABLY AN ALLOGRAFT WITH A 70/30 CANCELLOUS/CORTICAL RATIO

Step 1:

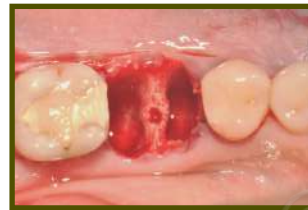Separate molar roots at the furcation without compromising the integrity of the septum. Perform atraumatic mesial and distal root extraction. Degranulate tissue to expose septum area.



Step 1

Step 2:

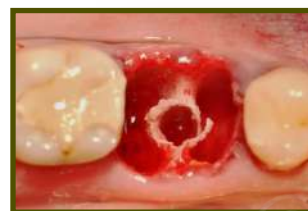Use a pilot drill that is 1.3 mm -1.5 mm, in clockwise mode, in the **center of the septum to a depth that is 1 mm deeper than the planned implant length.**



Step 2

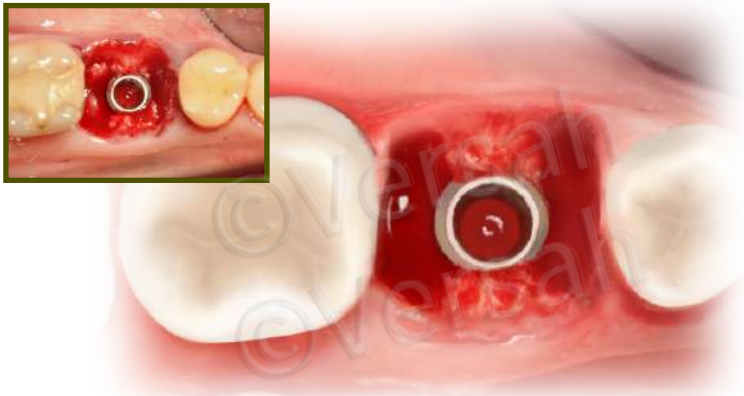Step 3:

Depending upon the implant type and diameter, follow the corresponding Implant System Drilling Protocol starting with the smallest Densah™ Bur to 1 mm deeper than the intended implant length. Run the Densah™ Burs in OD mode (counterclockwise, drill speed 800-1500 rpm with copious irrigation). **Use the subsequent Densah™ Burs in smaller increments to increase bone plasticity and to expand the osteotomy. For example, use Densah™ Bur (2.0) after the pilot then expand with Densah™ Bur (2.3) then move to Densah™ Bur (2.5) before introducing the Densah™ Bur (3.0).** As it is in ridge expansion cases with Osseodensification, you may over-expand the osteotomy so the last Densah™ Bur diameter is slightly larger than the planned implant major diameter. As the bur diameter increases, the bone expands to reach the final osteotomy diameter.



Step 3

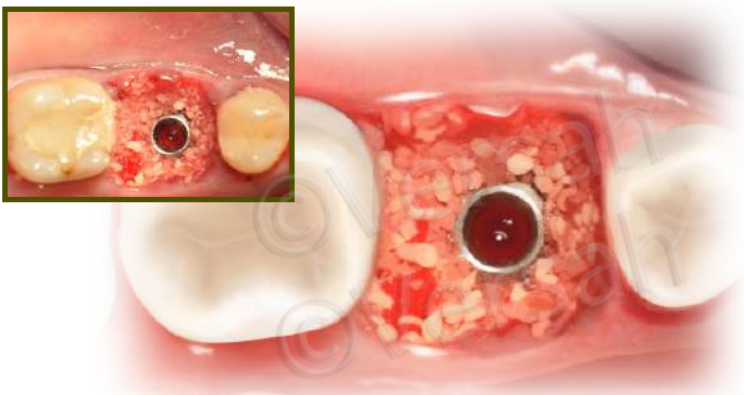
Step 4



Step 4:

Implant placement should be either at the crest level or sub-crest level depending on its connection type.

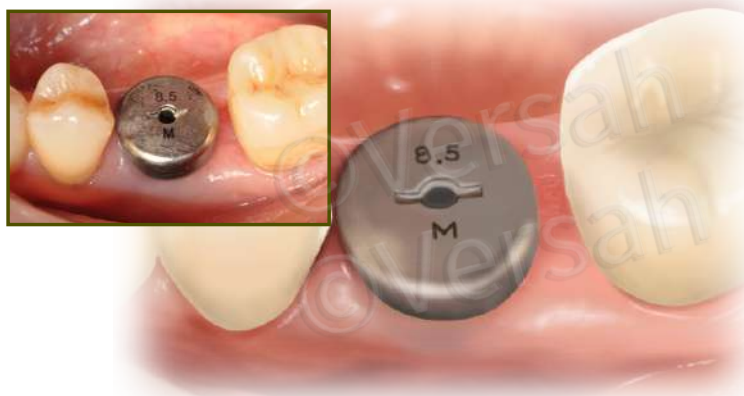Step 5



Step 5:

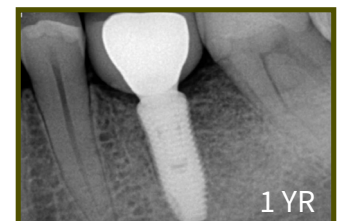
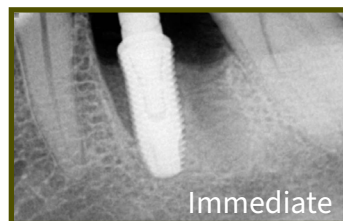
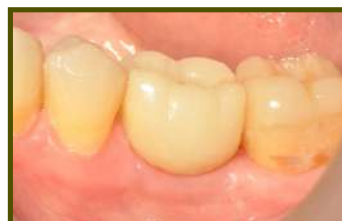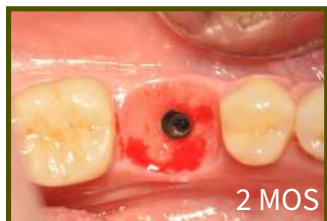Fill the gap with a bone graft material if needed; preferably an allograft with a 70/30 cancellous/cortical ratio. Seal the gap with biologics or a collagen plug and a large healing abutment and possibly place interrupted suture on top.

Step 6



Step 6:

Assess healing and soft tissue closure 6-8 weeks post placement.



Case courtesy of Dr. Samvel Bleyan